


Postdissection Aneurysms

Devices and techniques for treating this condition.

BY GEORGE N. KOUVELOU, MD; TILO KÖLBEL, MD, PhD;
ATHANASIOS KATSARGYRIS, MD; NIKOLAOS TSILIMPARIS, MD, PhD;
KYRIAKOS OIKONOMOU, MD; AND ERIC L.G. VERHOEVEN, MD, PhD



Chronic type B aortic dissection (indication to treat: postdissection aneurysm) constitutes a unique condition that needs a different treatment strategy than applied in the treatment of acute or subacute type B aortic dissection. In acute type B dissection, the main goal is to close the entry tear and redirect blood flow to the true lumen, or to correct organ ischemia. In chronic type B dissection, the challenge is to prevent aneurysmal degeneration. As a postdissection aneurysm usually involves the thoracoabdominal

aorta, the repair involves taking care of the visceral branches of the aorta in most cases. Open repair is very technically demanding and is associated with high mortality and morbidity, and the role of endovascular techniques in the treatment of chronic dissection is not yet defined.¹⁻³

INDICATION

Diagnosis and management of acute aortic dissection have improved significantly during the last decades. Nevertheless, a number of surviving patients will develop a postdissection aneurysm. Ongoing aortic dilatation is usually the one indication in chronic type B dissection, while malperfusion rarely occurs years after the acute dissection. The extensive remodeling of the aorta with a small true lumen and the increasing fibrotic stiffness of the intimal flap represent an anatomy with specific technical challenges.

TREATMENT OPTIONS FOR POSTDISSECTION ANEURYSM

Open Repair

Due to many patients being unfit for such a major

procedure, open surgical repair of postdissection thoracoabdominal aortic aneurysms (TAAAs) has been associated with significant risks. Current data focusing exclusively on open surgical repair of secondary postdissection aneurysms are limited to high-volume centers with significant experience in complex open aortic surgery.⁴ Tian et al conducted a systematic review of literature on open surgical repair for chronic type B dissection and found 19 studies, which included 970 patients.⁵ Overall, pooled short-term mortality was 11.1%, while stroke, spinal cord ischemia (SCI), renal dysfunction, and reoperation for bleeding occurred in 5.9%, 4.9%, 8.1%, and 8.1% of the patients, respectively. Late reintervention was needed in 13.3% of the patients, and aggregated survival at 3, 5, and 10 years was 74.1%, 66.3%, and 50.8%, respectively. Although these poor outcomes were partially attributed to patient selection and the extent of open surgery, because most centers selectively reserved open repair for patients with extensive diseases, it is clear that open surgical repair is an extensive procedure and should only be considered for patients in reasonably good condition.

Standard TEVAR

Thoracic endovascular aneurysm repair (TEVAR) is an established treatment in acute and subacute dissections that seems to promote false lumen thrombosis and aortic remodeling;⁶ however, the role of TEVAR in treating patients with chronic type B dissection is not well defined. In a systematic review of midterm outcomes of TEVAR for chronic type B aortic dissection, Thrumurthy et al reported a nearly 90% technical success rate and 3.2% 30-day mortality rate.⁷ However, the midterm reintervention rate of up to 60% was detailed, while nearly 10% of the patients developed aneurysmal progression of the aorta. In a small study of 76 patients, TEVAR resulted in a significantly decreased aortic diameter along the stent-grafted segment, but not in the distal untreated segments.⁸ A recent study by Mani et al showed that total false lumen thrombosis occurred in only one-third of patients after TEVAR and was more common in dissections confined to the thoracic aorta (83%)

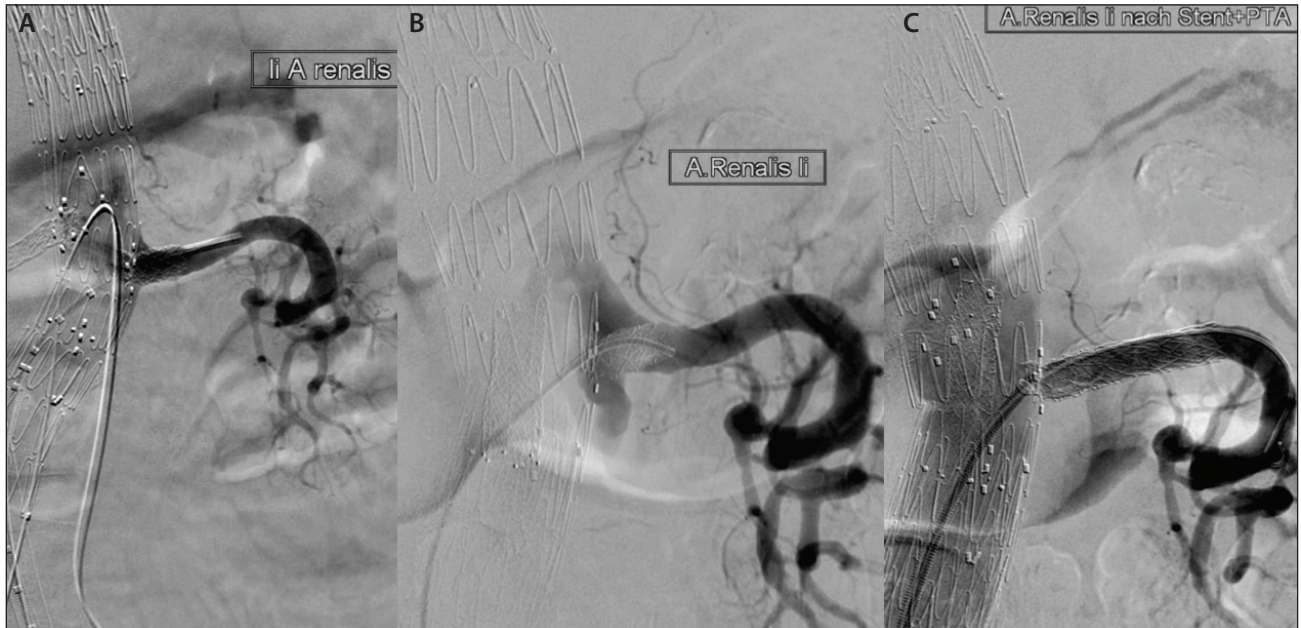


Figure 1. Completion angiogram after endovascular treatment of a postdissection aneurysm showing left renal artery patency with no sign of an endoleak (A). Selective angiography during follow-up showing a type Ib endoleak originating from the left renal artery (B). The endoleak was treated with distal extension of the covered renal bridging stent with an Atrium Advanta V12 stent graft (Maquet Vascular Systems) (C).

than those extended to the abdominal aorta (23%).⁹ Therefore, standard TEVAR seems to play a minor role in the treatment of chronic type B dissection, and only for postdissection aneurysms limited to the thoracic aorta. In patients with extensive postdissection aneurysms, TEVAR plays no role.¹⁰

Treatment With Fenestrated and Branched Grafts

To achieve a complete exclusion of the thoracoabdominal aneurysmal degeneration, a more extensive endovascular approach with fenestrated and branched (F/Br) stent grafts was attempted; however, only in recent years and only by a few expert centers.¹¹⁻¹³ Early on, the specific anatomy in postdissection aneurysms discouraged even expert centers to address this pathology with F/Br grafts. A narrow aortic true lumen characterizes most of the cases and complicates planning. Fenestrations require less true lumen space for deployment, although the planning of the orientation of the fenestrations is more tedious than that for the treatment of standard TAAA. Branches are easier to plan, while the cannulation of target vessels may be simpler with a sharp take-off over a transaxillary access. Nevertheless, branches require more working space that is usually lacking in the narrow true lumen. Visceral branches originating from the false lumen create technical difficulties for catheterization. Different techniques have been used to perforate the dissection flap: wires with tips that can be stiffened, the back of a wire,

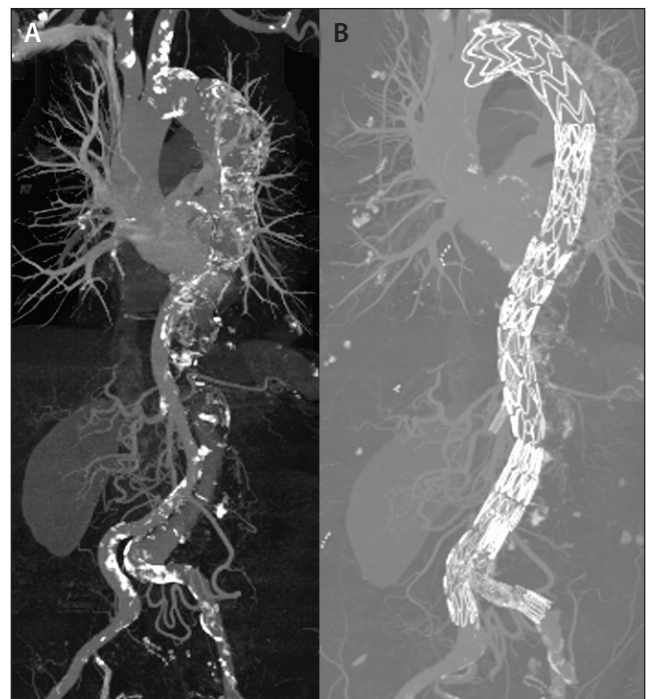


Figure 2. CT angiography (CTA) of a patient with a postdissection thoracoabdominal aortic aneurysm (A). CTA 2 years after endovascular treatment with fenestrated and branched stent grafting showing expansion of the true lumen and shrinkage of the false lumen (B).

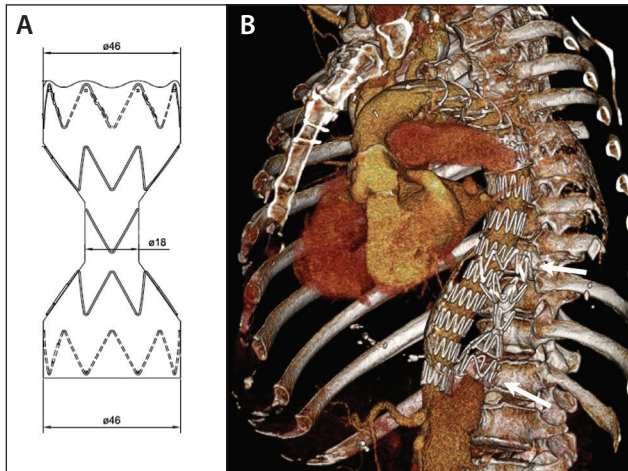


Figure 3. Technical drawing of a 46-mm Candy-Plug (A). 3D volume rendering of the postoperative CTA showing a patient after TEVAR extension to the celiac artery after previous frozen elephant trunk repair and Candy-Plug occlusion of the false lumen at the distal descending thoracic aorta (arrow) (B).

a wire with support of a guiding sheath, or even a TIPPS needle. Also, the distal landing zone can be compromised when the dissection extends to the common iliac arteries. Hypogastric artery flow should be preserved to reduce the risk of paraplegia. This can be achieved by incorporating an iliac branched device (IBD) to the repair plan, or by landing in a dissected common iliac artery and hoping for adequate sealing.

Data from the literature are still scarce and lack longer follow-up. Kitagawa et al reported the Cleveland Clinic experience on 30 patients with chronic dissection (15 focal and 15 with thoracoabdominal extent) treated with F/Br-EVAR.¹³ Technical success was achieved in all patients, and no perioperative deaths occurred. One aortic-related death occurred at 3 months due to progression of a pre-existing untreated arch dissection. No ruptures, cardiac, renal, pulmonary, or SCI complications occurred. Also, no graft compression was noted, despite the initially narrow true lumen dimensions. During a mean follow-up period of 1.7 years, aneurysm sac growth was noted in two patients, related to type II endoleaks, which were treated with translumbar glue embolization. Eight (26.7%) patients (five with type I and three with type III endoleaks) underwent reintervention, with four patients requiring multiple endovascular procedures.

The Nuremberg experience in the treatment of postdissection thoracoabdominal aneurysm with F/Br-EVAR includes 31 patients (26 male, mean age 65 ± 9.6 years) treated between October 2010 and August 2015. Part of this experience was published before.¹¹⁻¹² All cases were technically successful, but in one case, a retroperitoneal approach was needed for renal artery catheterization.

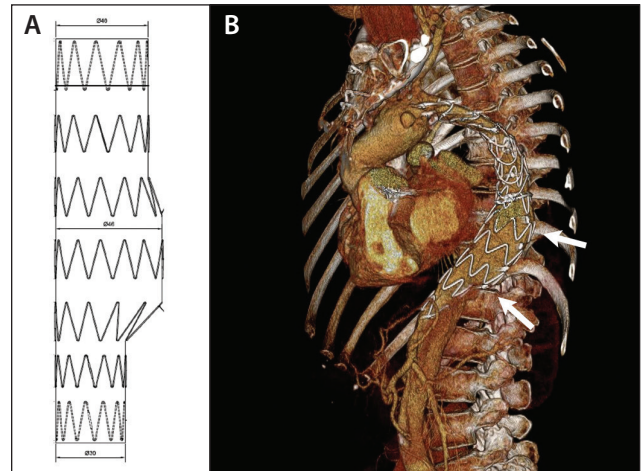


Figure 4. Technical drawing of a Knickerbocker graft with a 46-mm midsection (A). 3D volume rendering of the postoperative CTA showing a patient after TEVAR extension to the celiac artery after a previous frozen elephant trunk repair using a Knickerbocker graft for occlusion of the false lumen at the distal descending thoracic aorta. Arrows point at the bulbous midsection (B).

Two (6.4%) patients died within 30 days postoperatively, one due to multiple organ failure and one due to cardiac failure. Renal function impairment occurred in one (3.2%) patient. Perioperative SCI occurred in five (16.1%) patients. One (3.2%) patient suffered paraplegia with significant improvement prior to discharge, and four (12.9%) patients suffered transient paraparesis with complete recovery prior to discharge. One (3.2%) patient developed late (6 months) SCI with urinary incontinence and lower limb weakness due to regression of a type II endoleak. Mean follow-up was 17.6 months (range, 1–54 months). There was one death due to an aorto-esophageal fistula 26 months postoperatively. Four target vessel occlusions were reported (three renal arteries, one celiac trunk) during follow-up. In one case, an iliac-renal bypass was carried out. One patient had a known occlusion of the left renal artery and became dialysis dependent after occlusion of the right renal artery stent graft. The remaining two cases were asymptomatic and did not require treatment. Endoleak was diagnosed in 13 (41.9%) patients during follow-up. These included five (16.1%) type Ib endoleaks (renal artery, $n = 4$; renal artery and superior mesenteric artery, $n = 1$), two (6.4%) distal type Ib endoleaks from dissected iliac arteries, five (16.1%) type II endoleaks, and one (3.2%) type III endoleak from a renal artery bridging stent graft. In four of the five patients with type Ib endoleak, a stent graft extension placed deeper into the target vessel resolved the problem (Figure 1). In the fifth patient with a type Ib endoleak, the renal artery stent graft was successfully reflowed. In one patient, a type II endoleak from a lumbar artery was treated with embolization. In one patient with

bilateral type Ib endoleak from iliac arteries, iliac branched devices were implanted bilaterally. Finally, the one type III endoleak was treated with a bridging stent in the renal artery. Aneurysm sac regression during follow-up was significant from 67.4 ± 6.4 mm to 59.1 ± 7.5 mm ($P = .007$), with a false lumen thrombosis rate of 77.7% for patients that completed 12-month follow-up (Figure 2).

Endovascular Techniques for Occlusion of the False Lumen

Continued false lumen perfusion limits the response to endovascular treatment in patients with chronic type B aortic dissection by retrograde flow arising from distal entry tears within the abdominal aorta and iliac arteries. Occlusion of these connections between the true and false lumens can be achieved by stent graft coverage using fenestrated and branched endografts into the iliac arteries. This strategy allows for complete false lumen thrombosis throughout the dissected thoracoabdominal aorta, but as described above, these interventions are challenging and carry significant risks, especially for spinal cord ischemia because all segmental arteries may be covered during the treatment.

A proportion of patients with postdissection aneurysms develop aneurysmal dilatation in the distal aortic arch and the proximal and mid-descending thoracic aorta alone, while the abdominal segment remains relatively normal, not requiring treatment. This subset of patients may be treated with a less complex procedure, with a lower risk for SCI. This can be achieved by using standard TEVAR covering the thoracic aorta down to the celiac artery in combination with techniques to occlude the false lumen. Three options are described below:

Direct false lumen occlusion. Embolization of the false lumen channel at the level of the distal descending thoracic aorta can be achieved by a variety of embolizing agents. This method was first described by Loubert et al as the “cork-in-the-bottle neck” strategy that places cava filters, detachable balloons, thrombin, and Talent occluders (Medtronic) into the false lumen to successfully achieve occlusion.¹⁴ Hofferberth et al described an extension of this method with the additional use of coils and cyanoacrylate glue in a study including 31 patients.¹⁵ Recently, Idrees et al reported on 21 patients with chronic thoracoabdominal aortic dissection who underwent iliac occluders to embolize the false lumen. A 100% technical success rate and false lumen thrombosis in all patients at a median follow-up of 25 months were reported.¹⁶ In patients with large false lumen diameters, embolization can be challenging, as commercially available materials for arterial embolization are not suitable for the large diameters required. To address the problem, two new techniques for direct false lumen occlusion at the level of the distal descending thoracic aorta were recently introduced, as described in the information to follow.

The Candy-Plug technique. Initially, this technique was introduced by using a 42-mm thoracic stent graft that was modified into a large candy-shaped plug by adding a diameter-restricting suture in the middle of the graft (Figure 3).¹⁷ The plug was positioned in the false lumen opposing the distal end of the endograft in the true lumen. The restricted mid-section of the stent graft requires occlusion by a large Amplatzer vascular plug (St. Jude Medical, Inc.). More recently, the Candy-Plug has been produced as a custom-made implant with a maximum diameter of 50 mm and a mid-section of 18 mm, allowing for retraction of the dilator tip of the introduction system. To date, at the University Heart Center Hamburg, Candy-Plugs have been used successfully in 10 patients with large false lumen diameters.

The Knickerbocker technique. With this technique, the false lumen is occluded by expanding a large-diameter stent graft placed in the true lumen, which ruptures the dissection membrane into the false lumen on a limited segment of aorta.¹⁸ After an initial experience with using oversized standard tubular stent grafts, custom-made double-tapered stent grafts with a bulbous section are used today. Gold markers direct the bulbous section toward the false lumen. The Knickerbocker graft is deployed within the intended segment of the aorta with a sufficient overlap to the proximal stent graft and ending proximal to the celiac artery (Figure 4). After orienting the gold markers toward the false lumen and deploying the graft, a compliant balloon is used to dilate the bulbous section of the stent graft until the dissection membrane ruptures in the intended segment of the aorta and the oversized stent graft expands into the false lumen, sealing off false lumen backflow. The resulting shape of the stent graft is similar to knickerbocker trousers, hence the denomination. At the University Heart Center Hamburg, Knickerbocker grafts have been used successfully in nine patients with large false lumen diameters.

CONCLUSION

Postdissection patients need treatment in case of aneurysmal degeneration. This aneurysmal degeneration usually involves the thoracoabdominal aorta. Open surgery represents a challenging procedure for both patients and physicians who are involved. Standard TEVAR plays virtually no role, as it cannot exclude the distal aneurysm. Fenestrated and branched endografts have been used with success, but longer follow-up is needed to demonstrate effectiveness and durability. Special endovascular techniques that aim at occluding the false lumen distally, using custom-made grafts to perforate the dissection flap or vascular plugs to embolize the false lumen, have demonstrated technical feasibility and could play a role in the subset of patients where the abdominal aorta is not involved. ■

George N. Kouvelos, MD, is with the Department of Vascular and Endovascular Surgery, Klinikum Nuernberg in Nuernberg, Germany. He has stated that he has no financial interests related to this article.

Tilo Kölbel, MD, PhD, is with the Department of Vascular Medicine, University Heart Center in Hamburg, Germany. He has disclosed that he is an intellectual property holder of Cook Medical, and he has received speaker fees, research grants, or consulting fees from Cook Medical. Prof. Kölbel may be reached at t.koelbel@uke.de.

Athanasios Katsargyris, MD, is with the Department of Vascular and Endovascular Surgery, Klinikum Nuernberg in Nuernberg, Germany. He has stated that he has no financial interests related to this article.

Nikolaos Tsilimparis, MD, PhD, is with the Division of Vascular Surgery and Endovascular Therapy, Emory University School of Medicine in Atlanta, Georgia. He has disclosed that he has no financial interests related to this article.

Kyriakos Oikonomou, MD, is with the Department of Vascular and Endovascular Surgery, Klinikum Nuernberg in Nuernberg, Germany. He has stated that he has no financial interests related to this article.

Eric L.G. Verhoeven, MD, PhD, is Chief, Department of Vascular and Endovascular Surgery, Klinikum Nuernberg, Paracelsus Medical University Nuernberg in Nuernberg, Germany. He has disclosed that he has received educational grants and is a consultant for Cook Medical, Gore & Associates, Siemens, AtriumMaquet, and Medtronic. He also provides educational speaker services to TriVascular, Inc.

Prof. Verhoeven may be reached at +49 9113982651; eric.verhoeven@klinikum-nuernberg.de.

1. Cowan Jr JA, Dimick JB, Henke PK, et al. Surgical treatment of intact thoracoabdominal aortic aneurysms in the United States: hospital and surgeon volume-related outcomes. *J Vasc Surg.* 2003;37:1169-1174.
2. Coselli JS, Bozinovski J, LeMaire SA. Open surgical repair of 2286 thoracoabdominal aortic aneurysms. *Ann Thorac Surg.* 2007;83:S862-S864.
3. Oikonomou K, Katsargyris A, Ritter W, et al. Endovascular management of chronic post dissection aneurysms. *Ann Cardiothorac Surg.* 2014;3:307-313.
4. Kouchoukos NT, Kulik A, Castner CF. Open thoracoabdominal aortic repair for chronic type B dissection. *J Thorac Cardiovasc Surg.* 2015;149:S125-S129.
5. Tian DH, De Silva RP, Wang T, Yan TD. Open surgical repair for chronic type B aortic dissection: a systematic review. *Ann Cardiothorac Surg.* 2014;3:340-350.
6. Kusagawa H, Shimono T, Ishida M, et al. Changes in false lumen after transluminal stent-graft placement in aortic dissections: six years' experience. *Circulation.* 2005;111:2951-2957.
7. Thrumurthy SG, Karthikesalingam A, Patterson BO, et al. A systematic review of mid-term outcomes of thoracic endovascular repair (TEVAR) of chronic type B aortic dissection. *Eur J Vasc Endovasc Surg.* 2011;42:632-647.
8. Kang WC, Greenberg RK, Mastracci TM, et al. Endovascular repair of complicated chronic distal aortic dissections: intermediate outcomes and complications. *J Thorac Cardiovasc Surg.* 2011;142:1074-1083.
9. Mani K, Clough RE, Lyons OT, et al. Predictors of outcome after endovascular repair for chronic type B dissection. *Eur J Vasc Endovasc Surg.* 2012;43:386-391.
10. Andacheh ID, Donayre C, Othman F, et al. Patient outcomes and thoracic aortic volume and morphologic changes following thoracic endovascular aortic repair in patients with complicated chronic type B aortic dissection. *J Vasc Surg.* 2012;56:644-650.
11. Verhoeven EL, Paraskevas KI, Oikonomou K, et al. Fenestrated and branched stent-grafts to treat post-dissection chronic aortic aneurysms after initial treatment in the acute setting. *J Endovasc Ther.* 2012;19:343-349.
12. Oikonomou K, Kopp R, Katsargyris A, et al. Outcomes of fenestrated/branched endografting in post-dissection thoracoabdominal aortic aneurysms. *Eur J Vasc Endovasc Surg.* 2014;48:641-648.
13. Kitagawa A, Greenberg RK, Eagleton MJ, et al. Fenestrated and branched endovascular aortic repair for chronic type B aortic dissection with thoracoabdominal aneurysms. *J Vasc Surg.* 2013;58:625-634.
14. Loubert MC, van der Hulst VP, De Vries C, et al. How to exclude the dilated false lumen in patients after a type B aortic dissection? The cork in the bottleneck. *J Endovasc Ther.* 2003;10:244-248.
15. Hofferberth SC, Nixon IK, Mossop PJ. Aortic false lumen thrombosis induction by embolotherapy (AFTER) following endovascular repair of aortic dissection. *J Endovasc Ther.* 2012;19:538-545.
16. Idrees J, Roselli EE, Shafiq S, et al. Outcomes after false lumen embolization with covered stent devices in chronic dissection. *J Vasc Surg.* 2014;60:1507-1513.
17. Kölbel T, Lohrenz C, Kieback A, et al. Distal false lumen occlusion in aortic dissection with a homemade extra-large vascular plug: the candy-plug technique. *J Endovasc Ther.* 2013;20:484-489.
18. Kölbel T, Carpenter SW, Lohrenz C, et al. Addressing persistent false lumen flow in chronic aortic dissection: the knickerbocker technique. *J Endovasc Ther.* 2014;21:117-122.